

PATIENT

Sadie Riskin

SPECIES

Canine

BREED

Lab Mix

SEX

Female Spayed

AGE

11 years

WEIGHT

NP

INTERPRETED BY

Maggie Machen Lamy,
 DVM, DACVIM
 (Cardiology)

IMAGING PERFORMED BY

Rebecca Hamilton

HOSPITAL NAME

Millburn Veterinary
 Hospital

REFERRING VET

Dr. Rotsides

INVOICE

46442

DATE

1/14/26

PRESENTING CLINICAL SIGNS

History: Recheck echo. Grade 2/6 heart murmur. Assess prior to anesthesia for mass removal.
 -Pertinent previous echo findings (11/2023 MML): CVD B1. Mild MR, trace TR, elevated LVOT. LA: 2.3, LV: 2.7.

ECHOCARDIOGRAM FINDINGS

2D, m-mode, color flow and doppler imaging is available. Diffuse thickening of mitral valve leaflets (anterior>posterior) with mild prolapse into the left atrial lumen. Moderate eccentric mitral regurgitation with moderate left atrial dilation. Normal MR velocity. Mildly increased LV diameter with hyperdynamic myocardial function. The tricuspid valve appears subjectively normal, with trace tricuspid regurgitation. Normal velocity. Normal right atrial and ventricular diameter. The pulmonic and aortic valves are normal in morphology and mobility. Normal pulmonic and aortic outflow velocities. No aortic or pulmonic insufficiency. No pericardial or pleural effusion noted. No cardiac tumors observed.

CARDIAC CHART

CANINE CARDIAC PARAMETERS	MR VMAX (m/s)	TR VMAX (m/s)	LA/AO (Boon method)	LA/AO (Heart Base; Swe)	FS (%)	EF (%)	EPSS (cm)
NORMAL PARAMETER	4.5-5.5	<2.7	1.3	<1.6	28-40	40-100	<0.6
PATIENT	6.2	2.7	NM	1.8	53	86	0.4
CANINE CARDIAC PARAMETERS	HR (BPM)	AV VMAX (m/s)	PV MAX (m/s)	BODY WEIGHT (kg)	LA 2D short axis Base view (cm)	LVIDd Avg; 2D and m-mode short axis (cm)	LVIDs Avg; 2D and m-mode short axis (cm)
NORMAL PARAMETER	50-100	0.7-1.7	0.7-1.6	BELOW	BELOW	BELOW	BELOW
PATIENT	85	2.1	1.0	NP	3.0	3.5	2.0
*Normal chamber parameters expressed as a mean value (SD)				3	1.27 (5.3)	2.46 (2.46)	1.36 (5.5)
BODY WEIGHT DEPENDENT PARAMETERS				5	1.40 (4.5)	2.74 (5.2)	1.60 (4.7)
*Note: All measurements based upon multi-modal images and methods. An average value is reported.				10	1.50 (3.8)	3.27 (3.5)	2.06 (3.1)
				15	1.83 (2.0)	3.71 (2.4)	2.43 (2.1)
				20	2.02 (1.9)	4.14 (2.2)	2.80 (2.0)
Adapted from June Boon, Veterinary Echocardiography, 1998				25	2.18 (2.4)	4.48 (2.9)	3.10 (2.5)
Rishniw M and Hollis NE, J Vet Intern Med 2000; 14:429-435				30	2.33 (3.3)	4.83 (3.9)	3.39 (3.4)
Hansson et al, Vet Rad and Ultrasound 2002				35	2.48 (4.3)	5.17 (5.0)	3.69 (4.5)
Bonagura et al. Echocardiography: principles of interpretation, Vet Clin North Am 15:1177, 1995				40	2.62 (5.2)	5.48 (6.1)	3.96 (5.4)
				50	2.88 (7.1)	6.07 (8.3)	4.46 (7.4)

INTERPRETATION OF THE FINDINGS & FURTHER RECOMMENDATIONS

Chronic degenerative valve disease persists with evidence of progression. Previously mild MR has advanced to moderate, with increasing left heart dimensions. The tricuspid leak is stable, without obvious additional issues such as pulmonary hypertension. Moderate left atrial enlargement indicates there is relatively low risk for imminent complication; however, risk for progression to spontaneous congestive heart failure in the future is now elevated.

Based upon these findings and the results of the EPIC trial, recommend institution of Pimobendan as below. Additionally, a baseline BP is recommended. Continued assessment of progression is recommended, with a guarded prognosis once in stage B2. Fifty percent of stage



PATIENT

Sadie Riskin

B2 patients typically develop CHF within 2-2.5 years of diagnosis. The median time to development of CHF in B2 cases treated with pimobendan is 3.5 years. Patient may be at risk for development of CHF, arrhythmias, and/or sudden death going forward.

SPECIES

Canine

Omega fatty acid supplementation and mild salt restriction may also be of some long-term benefit. Monitor for development of a progressive cough, labored breathing, exercise intolerance or collapse episodes.

BREED

Lab Mix

Once on the medication for 3-5 days, anesthetic risk remains mildly elevated. Cardiac protective drug choices (opioid/benzodiazepine premedication, Propofol or alfaxalone induction, iso or sevo gas) are recommended. Monitor for arrhythmias, hypotension, and hypoxia both intra and post-operatively and intervene as necessary. Judicious IV fluid rates are recommended to avoid fluid overload. Avoid heart rate stimulating drugs such as atropine unless clinically indicated.

SEX

Female Spayed

PLAN

Baseline BP recommended every 6 months. Institute Pimobendan 0.25-0.3mg/kg PO q12h.

AGE

11 years

Recommend monitor for progression with a recheck echocardiogram in 6 months, sooner if any development of clinical signs.

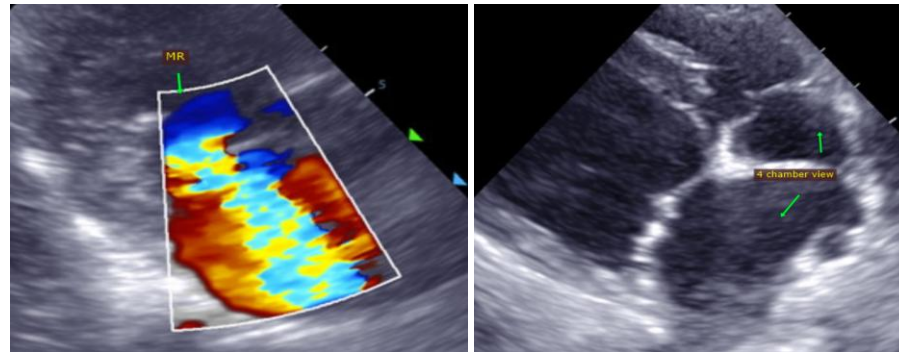
WEIGHT

NP

IMAGES

INTERPRETED BY

Maggie Machen Lamy,
 DVM, DACVIM
 (Cardiology)



IMAGING PERFORMED BY

Rebecca Hamilton

The information and recommendations provided are based on the images presented by the referring veterinarian. No evaluation can be communicated regarding pathology that was not visible in the image/video clips provided.

HOSPITAL NAME

Millburn Veterinary
 Hospital

Thank you for this referral. This report was generated using transcription software, and minor dictation errors may be present. If the clinical or image interpretation does not parallel your findings or if I can be of any further assistance, please contact me.

REFERRING VET

Dr. Rotsides

Maggie Machen Lamy, DVM
 Diplomate of the American College of Veterinary Internal Medicine (Cardiology)
 info@sonopath.com

INVOICE

46442

DATE

1/14/26